

The temporomandibular joint and the disc-condyle relationship after functional orthopaedic treatment: a magnetic resonance imaging study

Nezar Watted*, Emil Witt* and Werner Kenn**

Departments of *Orthodontics and Dentofacial Orthopaedics and **Magnetic Resonance Tomography, Bavarian Julius-Maximilian-University Würzburg, Germany

SUMMARY Causative correction of Class II skeletal malocclusions may be achieved through bite jumping by various means. Numerous animal experiments have yielded evidence of remodelled temporomandibular structures after mandibular protrusion. However, the mode and extent of structural and/or topographic changes of the disc-condyle relationship after functional orthopaedic treatment is still unresolved.

A problem exists in defining the physiological position of the condyles and disc-condyle relationship, which is tentatively determined by various methods particularly in magnetic resonance tomographic studies. Despite the high resolution provided, the results have to be interpreted with caution, as osseous resorption and apposition cannot be assessed by visual evidence.

This investigation examined the impact on the temporomandibular joints (TMJ), i.e. the condylar shape and position, and the disc-condyle relationship, of the bionator plus extra-oral traction in combination with vertical elastics. The underlying reactions were studied by means of magnetic resonance images (MRI) obtained from $n = 15$ successfully treated patients (mean age 11.6 years).

Introduction

Skeletal discrepancies between the maxilla and the mandible in the sagittal, transverse, and vertical planes pose a challenge to the orthodontist. While slight deviations are amenable to dento-alveolar interventions at any age, the question remains whether and what severity of sagittal anomalies, such as Angle Class II malocclusions, can be treated successfully in adolescent patients so as to avoid the need for later orthognathic surgery.

Although modalities have been suggested for treatment of Class II malocclusions (McNamara *et al.*, 1966; Armstrong, 1971; Petrovic *et al.*, 1973; Witt, 1973, 1988; Teuscher, 1978; Gianelly *et al.*, 1983; Stutzmann and Petrovic, 1987; Gianelly, 1998; Reuther, 1988), functional orthopaedic treatment using bimaxillary appliances during growth is controversial.

This treatment approach assumes that functional muscular stimuli are transmitted by the appliance to the periodontal structures, but also exert an influence on the temporomandibular joint (TMJ) region, where remodelling in the glenoid fossa and the condyle is triggered (Häupl and Psansky, 1939). This contrasts with the American doctrine of the 1970s, which regarded mandibular growth as genetically determined and, hence, not amenable to therapy (Ricketts, 1952; Armstrong, 1971; Coben, 1971).

Increased cell division activity in the condylar cartilage and additional sagittal growth during mandibular protrusion has been found (Stöckli and Willert, 1971; Petrovic *et al.*, 1974; McNamara *et al.*, 1975; Stutzmann and Petrovic, 1986). Komposch (1982) observed a posterior rotation of the condyles, an increased cartilage layer in the posterior and resorption in the anterior zone of the condyle, and anterior lengthening of the

glenoid fossa with morphological posterior translation of the mandibular ramus.

Functional orthopaedic appliances with various modifications were devised with varying success to make clinical use of the experimental evidence. The mode and extent of the skeletal response depended upon the morphology of the facial skeleton, the intensity and pattern of growth, and the method of intervention. The therapeutic bite position determined by the construction bite is crucial to the remodelling processes, which take place in the TMJ area (Petrovic and Stutzmann, 1988).

Bimaxillary appliances have increasingly been combined with extra-oral devices, e.g. the activator plus headgear (Teuscher, 1976, 1978, 1979) or the bionator plus J-hook headgear (Witt *et al.*, 1990; Witt, 1996) to enhance the effectiveness of treatment (Figure 1a,b).

It has been assumed that after bite jumping, muscular adaptation to the target position occurs in the lower arch. This suggestion implies that relapse may occur some time after discontinuation of the bimaxillary appliance. A drawback of the studies mentioned is that stability of the new mandibular position was not examined. By means of a bite plane applied for some weeks, the muscles are relieved and deprogrammed, so that merely muscular maintenance of the new mandibular position is prevented. Thus, the new position of the mandible can be examined (Witt and Watted, 1999).

Clinical techniques

Various modifications have been suggested to counteract the problem of failure to keep the mandible in the therapeutic position during the night, for example, building magnets into double plates (Vardimon *et al.*, 1989, 1990). According to the system used at the Würzburg Department of Orthodontics, the therapeutic bite position is secured during the night by inserting vertical elastics (also referred to as 'up and down elastics'). This simple and well-tolerated method effectively prevents the mandible from 'dropping out' during the night and guarantees passive adaptation during sleep. In connection with the anterior extra-oral

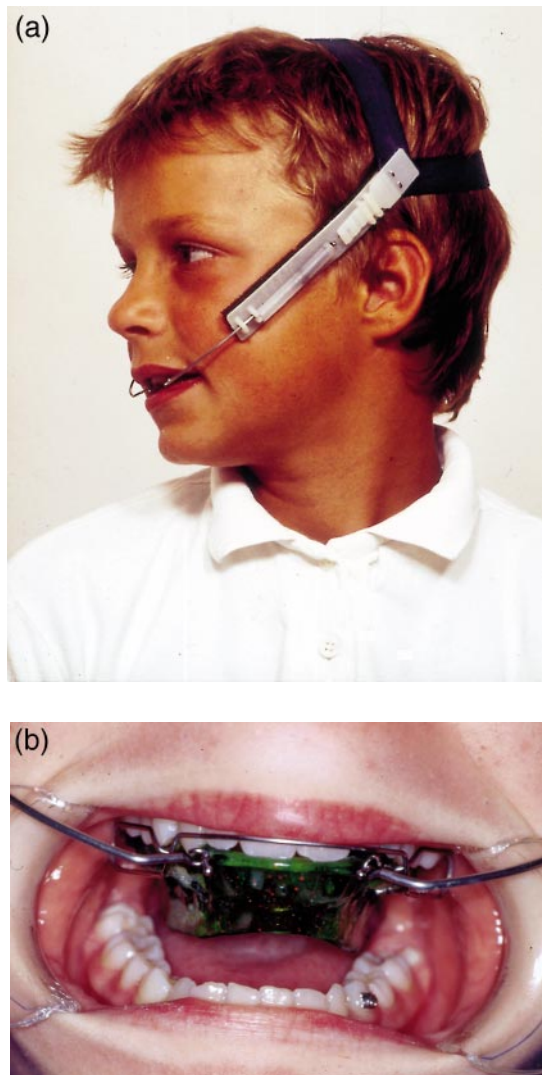


Figure 1 (a) Anterior traction, mouth-closing not restricted. (b) Bionator with anterior traction, fixation of the appliance to the maxilla by the anterior traction; the bionator must not drop from the upper lateral teeth on mouth opening.

traction retaining the bimaxillary appliance to the maxilla and thus exerting a growth-inhibiting effect on the maxilla (Figure 1a,b), attachments are bonded to appropriate mandibular teeth (either canines, first premolars, or first deciduous molars). Brackets or buttons are used for attachment and allow the insertion of elastics during the night. The latter run from these attachments

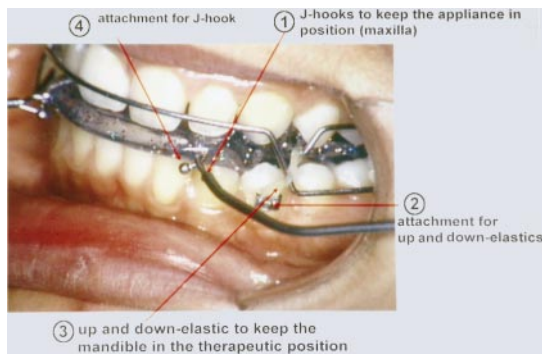


Figure 2 Treatment combination *in situ*.

to the J-hooks, balls, or to the buccinator extensions of the bimaxillary appliance (Figure 2).

While fixing the attachment, there has to be sufficient space between the buccinator extensions of the labial wire of the bimaxillary appliance (bionator) and the attachment. The elastics are selected so that the forces exerted on the mandible are below 100 g. The mandible is kept in the therapeutic position determined by the construction bite at night by the vertical elastics, thus providing the local conditions required for condylar growth adaptation (Petrovic and Stutzmann, 1988).

The clinical effectiveness of treatment of Class II malocclusions according to the above system was recently reported (Witt and Watted, 1999). Ten male and 10 female patients displaying Angle Class II division 1 malocclusions (mean age 11.6 years), and requiring bite correction of 6 mm or more were treated for 1 year, and compared with matched controls left untreated for 2 years. The SNA angle was reduced in the treated group from 82.2 to 81.6 degrees ($\bar{x} = -0.6$ degrees), but more importantly, the SNB angle increased from 75.7 to 76.8 degrees ($\bar{x} = 1.1$ degrees, $P < 0.05$). The corresponding reduction of the ANB angle averaged -1.7 degrees, and the facial convexity was reduced from 5.5 to 4.3 mm.

The central position of the condyle and the disc-condyle relationship

The definition of the physiological position of the condyle in the articular fossa and the

disc-condyle relationship is fundamental to radiographic or magnetic resonance imaging (MRI) evaluation of the TMJ structures. The variety of suggestions defining the physiological, i.e. 'correct' position of the condyles, has led to confusion, rather than to conceptual clarity (Posselt, 1952; Gerber, 1964; Boucher and Jacoby, 1968; Celenza, 1973; Kubein and Jähnig, 1983; Dawson, 1995).

The Academy of Prosthodontics (1994) defined centric relationship as the spatial relationship between the maxilla and the mandible, where the condyles relate to the articular eminence in a ventro-cranial position with the pars intermedia of the disc. The mandibular condyle is normally located in the centre of the mandibular fossa, with the cranial pole of the condyle and the most concave spot of the mandibular fossa being located in the same vertical plane (Figure 3). This approach is readily examined by means of MRI and was therefore employed in this study.

The posterior pole of the disc resting on the condyle in an 11–12 o'clock position indicates a normal disc-condyle relationship with a closed-mouth physiological position of the condyle in the fossa. This topography corresponds to 0 to -30 degrees with reference to the Y axis (Figure 4a). With increasing mouth opening, the posterior pole of the disc moves further dorsally and is located in a 12–1 o'clock position with a mouth opening of 4 mm, corresponding to 0–30 degrees with reference to the Y axis (Figure 4b).

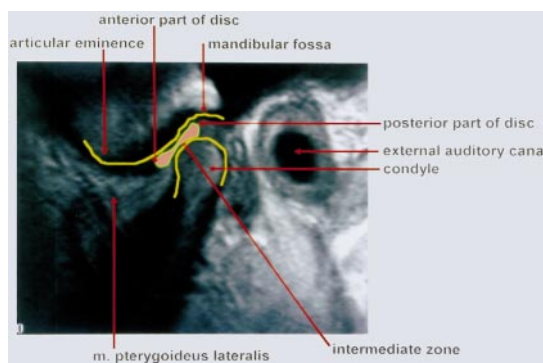


Figure 3 MRI with graphical visualization of the structures.

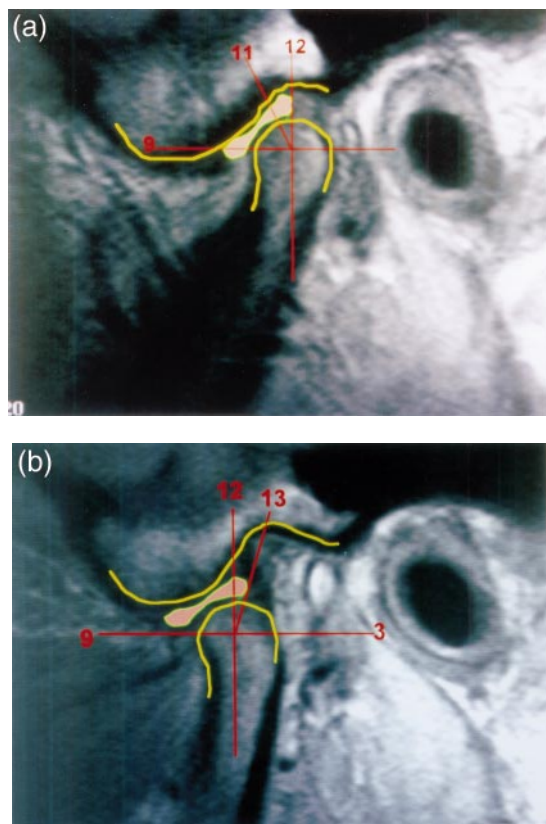


Figure 4 MRI of the TMJ in centric relationship, normal position of the condyles (with the cranial pole of the condyle and the most concave spot of the fossa mandible being located in the same vertical plane, 12 o'clock position) and disc-condyle relationship (a) with closed mouth (the posterior pole of the disc is resting on the condyle in an 11–12 o'clock position) and (b) with open mouth (the posterior pole of the disc moves further ventrally and is located in a 12–1 o'clock position).

Any deviation from these positions is referred to as disc displacement (Vogl *et al.*, 1988; Drace and Enzmann, 1989; Drace *et al.*, 1990).

If the mandible is moved into the intended sagittal, transverse, and vertical therapeutic position to the maxilla by the construction bite, the position of the condyles is out of centric. The condyles are moved ventrally from their central position within the mandibular fossa in the direction of the articular tuberculum. Accordingly, the disc-condyle relationship changes. Of special interest in this investigation was the disc-condyle relationship after bite jumping

had been completed by functional orthopaedic treatment.

Methods for the study of the TMJ

The effects of functional orthopaedic appliances on the condyle and fossa can be assessed based on conventional roentgenographic procedures, panoramic radiographs, or computer tomographic scans. However, only bony structures are visualized by these methods, while soft tissue structures and particularly the articular disc are not displayed. Moreover, the radiation dose is relatively high. The reproducibility of these recordings is also questionable despite the use of reference patterns (Weinberg, 1972).

MRI is particularly suited for the assessment of fossa-disc and disc-condyle relationships. This method allows the determination of the morphological TMJ structures depending on mouth opening (Vogl *et al.*, 1988; Schellas *et al.*, 1989; Wilk and Wolford, 1989; Tasaki and Westersen, 1993) and the classification of various TMJ findings existing in a given patient sample. Quantitative methods, however, are preferred for recognition of subtle differences in a largely normal study group.

Katzberg *et al.* (1985a,b) suggested a relatively simple and well-tried method to determine the spatial disc-condyle relationship (Drace and Enzmann, 1990; Glatzl, 1993). This approach was given preference in the present study among the variety of relevant approaches (Gerber, 1971; Weinberg, 1972; Ismail and Rokni, 1980; Katzberg *et al.*, 1983, 1985a,b; Owen, 1984a,b,c; Drace and Enzmann, 1989; Bell and Yamaguchi, 1991; Braun, 1996).

The so-called 12 o'clock position is referred to as the physiological closed-mouth position of the disc, as the transition of the pars posterior of the disc to the bilaminar zone is presumed to be located above the highest point of the condyle in the closed-mouth position.

Moreover, the MRIs allow examination of the position of the condyle in the mandibular fossa after bite jumping (Figure 4). Again, various approaches have been suggested. In contrast to the determination of the Joint Space Index developed by Kamelchuk *et al.* (1996), this study

relied on the approach described by Gerber (1970, 1978a,b) and utilized by Owen (1984a,b,c). According to this approach, the zenith of the condyle is presumed to be located opposite to that of the fossa. This procedure allows a more reliable determination of the reference points for measurement (anterior, posterior, and cranial pole of the condyle, posterior pole of the disc, centre of the mandibular fossa).

Aim

Beyond the appraisal of clinical effectiveness, the evaluation of this treatment regime requires the need to examine the condition of the TMJs. This prospective study was designed to investigate the condylar shape and the position in the mandibular fossa as well as the disc-condyle relationship in terms of MRI findings after bite correction was accomplished utilizing the bionator plus headgear in combination with vertical elastics.

Subjects and methods

Subjects

This study comprised 15 patients (seven males, eight females, mean age: 11.6 ± 0.5 years) randomly selected from a larger clinical sample (Witt and Watted, 1999) showing Angle Class II division 1 malocclusions and an initial need for bite jumping of 6 mm or more, who were treated with the bionator plus extra-oral traction and vertical elastics (Figures 1a,b and 2). All patients were instructed to wear the appliance for 14–16 hours per day. Extra-oral traction and vertical elastics were prescribed only at night in order to leave daily function unaffected. Entry criteria for the prospective study were successful bite correction to neutral occlusion and, thus, correction of the overjet.

After 12 months and bite jumping to the intended therapeutic position and prior to obtaining the intermediate records, a bite plane was applied for 2 weeks. With prescribed daily wear of 24 hours, this measure aimed at disclusion and muscular deprogramming (Figure 5). Thus, the stability of the mandibular position was examined to determine whether this resulted

solely from a muscular reaction or from growth adaptation of the bony structures. Moreover, the centric position of the condyles was determined, which was changed ventrally in the direction of the articular tuberculum through the construction bite.

Following discontinuation of the bite plane, i.e. after stability of the Class I occlusion with normal overjet was achieved, MRIs of the joints were obtained in order to study the shape and position of the condyles within the mandibular fossa, the shape of the fossa, and the disc-condyle relationship. Only 15 subjects were randomly selected from the larger sample for inclusion in the MRI study due to financial constraints.

MRI examination

The MRI scans of the joints were obtained according to the same procedure in all patients: both joints were scanned in the open- and closed-mouth position, i.e. habitual (neutral) occlusion. For fixation of mouth opening during the scans, a standardized plastic wedge of 4 cm was inserted between the arches in all patients.

The MRIs were obtained by means of a 1.5-T high field scanner (Siemens Magnetom Vision, München, Germany) with a special surface coil (TMJ coil). An optimized proton-weighted TSE (turbo factor 5) sequence (TR 1600 ms, TE

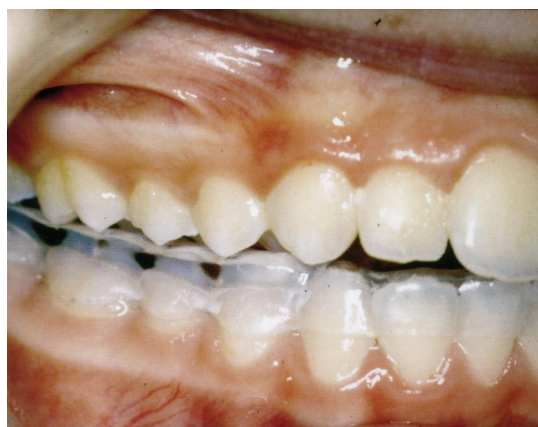

Figure 5 Bite plane (splint) designed for disclusion after bite jumping and control of bite stability.

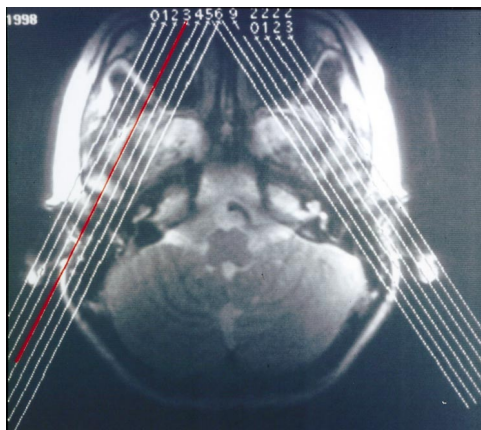


Figure 6 Angulated parasagittal slices, thickness 3 mm, for MRI in the open- and closed-mouth position.

15 ms) in an angulated parasagittal position with a slice thickness of 3 mm and a 512-matrix (field-of-view 170 mm) was used (Figure 6). The mean measuring time was 2.08 minutes after triple averaging.

The computer-assisted analysis of the MRIs of the 30 joints was conducted by one orthodontist and two radiologists. The inter-rater measurement error (lines and angles) was negligible. The central position of the condyles in the mandibular fossa and the disc-condyle relationship was analysed. Both parameters were assessed according to the definitions of Gerber (1971) and Vogl *et al.* (1988).

Position of the condyles. To assess the spatial relationship of the zeniths of the condyle, the longitudinal axis of the condyle was determined as follows: the anterior and posterior pole of the condyle was established (both are readily recognized on the MRIs). A connecting line was drawn between these points of reference. From the centre of this line, a perpendicular line was dropped cranially (Y axis), intersecting the cranial pole of the (sound) condyle. Another line was drawn from the constructed centre to the centre of the mandibular fossa, which is defined as the point of maximum concavity (Figure 7). If the two lines coincided, the condyle was in a centric position, i.e. in its ideal

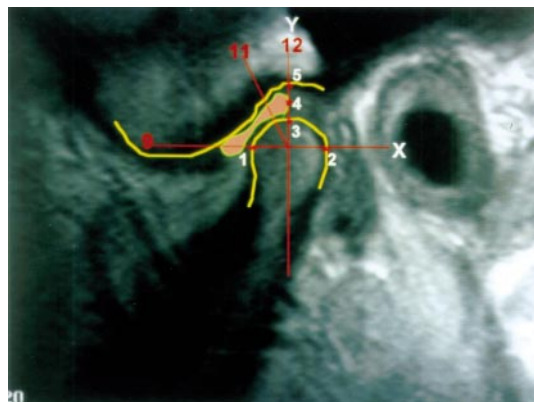


Figure 7 Reference points for measurement. 1, Anterior pole of the condyle; 2, posterior pole of the condyle; 3, cranial pole of the condyle; 4, posterior pole of the disc; 5, centre of the mandibular fossa.

physiological position within the mandibular fossa. If an angle was formed by the two lines, the condyle was in a posterior (positive values) or anterior position (negative values).

Disc-condyle relationship. The disc-condyle relationship was assessed within the open- and closed-mouth positions. After determination of the longitudinal axis of the condyles (Y axis), the posterior pole of the disc was marked. A line was drawn between the constructed centre in the condyle and the posterior pole of the disc (Figure 7). The shape of the condyles and the mandibular fossa was assessed visually.

Results

Clinical analysis

Functional analysis showed no pathological changes or functional restrictions of the joints and muscles. No patient displayed a conspicuous discrepancy between the occlusion achieved through bite jumping, and the centric position before and after insertion of the bite plane indicating skeletal and muscular adaptation, and hence a stable position of the mandible. Existing dysfunctions, e.g. of the lips, were eliminated by reduction of the overjet (Witt and Watted, 1999).

MRI analysis

Shape of the condyles and the fossa. The MRIs showed a physiological shape of the fossa and the condyles in both the open- and closed-mouth positions.

Disc-condyle relationship. Analysis of the MRIs revealed a physiological disc-condyle relationship in all patients. With closed mouth, the disc was located in relation to the condyle at an average position of -18.8 ± 3.9 degrees with reference to the Y axis. The maximum deviation of the disc from 'point 0' was -27.2 degrees, the minimum deviation was -12.1 degrees.

With open mouth, the disc was located in relation to the condyle at a position of $+25 \pm 5.2$ degrees on average, with a maximum deviation of $+32.1$ degrees and a minimum deviation of $+14.9$ degrees (Table 1).

Position of the condyles (centric position). Fifty-five per cent of the condyles displayed a deviation with reference to 'point 0' of the Y axis, i.e. the zenith of the condyle was located dorsally or ventrally from the Y axis. Seventy-five per cent of the condyles showed a dorsal deviation from the Y axis (positive value) and 25 per cent a ventral deviation (negative value). The deviation from the centre of the mandibular fossa averaged $+0.5 \pm 1.5$ degrees, with a minimum of -3 and a maximum of $+3$ degrees (Table 2).

Table 1 Position of the disc in relation to the condyle after bite jumping.

	<i>n</i>	Min/max (°)	Mean (°)	SD (°)
MRI1 (closed)	15	$-12.1/-27.2$	-18.8	3.9
MRI2 (open)	15	$+14.9/+32.1$	$+25.3$	5.2

Table 2 Position of the condyle in relation to the mandibular fossa after bite jumping (closed mouth).

	<i>n</i>	Min/max (°)	Mean (°)	SD (°)
MRI1 (closed mouth)	15	$-3/+3$	$+0.5$	1.5

Discussion

Treatment using the bionator plus high-pull traction in combination with vertical elastics leads to stimulation of mandibular growth and an inhibition of maxillary growth, which was shown in a controlled study (Witt and Watted, 1999). Growth stimulation is enhanced when the mandible is secured in the bite position. This effect is due to the mandible being prevented from dropping out of the 'therapeutic position' during sleep by means of vertical elastics. Thus, the local conditions needed for adaptation, remodelling, and morphological translation of the joint structures and their surroundings are provided. Adaptation proved to depend upon the time interval during which the mandible and the condyle were kept in the intended position (Witt and Watted, 1999).

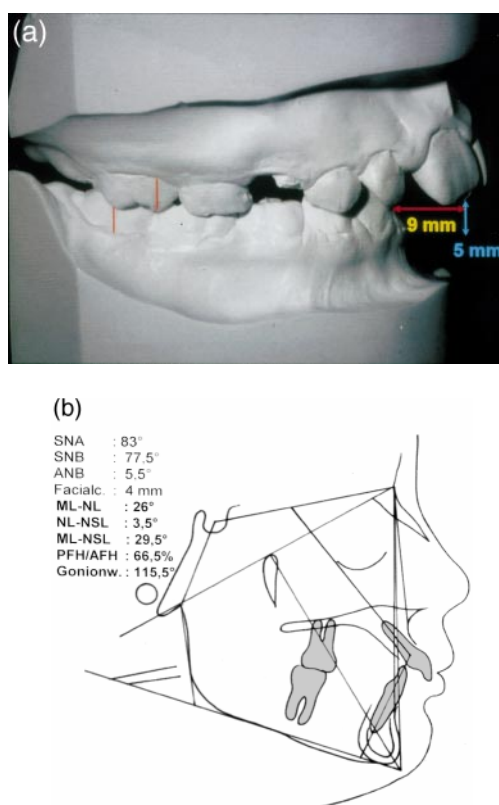


Figure 8 (a) Models and (b) lateral cephalogram tracing of an 11-year-old patient before treatment.

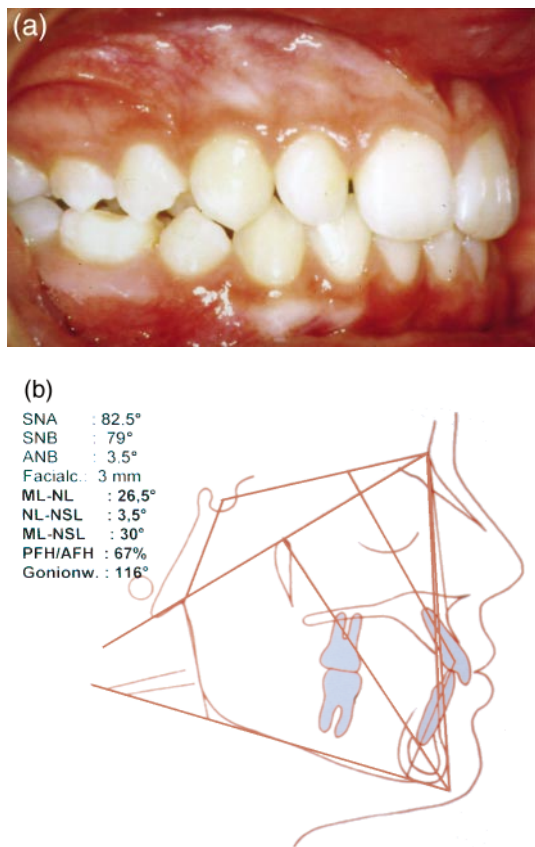


Figure 9 (a) Clinical situation and (b) lateral cephalogram tracing after bite correction and 3 weeks after insertion of a bite plane.

After bite jumping and initial ventral movement of the condyles from the fossa towards the articular tuberculum by means of the construction bite, a physiological shape and position of the condyles and the mandibular fossa were seen on the MRIs, as shown by the typical example given in Figure 8. This 11-year-old female patient displayed a distal occlusion with increased overjet and overbite (Figure 8a,b). She underwent treatment according to the procedure described above (bionator, anterior traction, vertical elastics). After bite jumping was completed, and neutral occlusion and correction of overjet and overbite was achieved, a bite plane was inserted for 2 weeks for disclusion and deprogramming of the muscles. Figure 9a,b shows a normal occlusion with normal overjet and overbite. The cephalogram shows a reduction

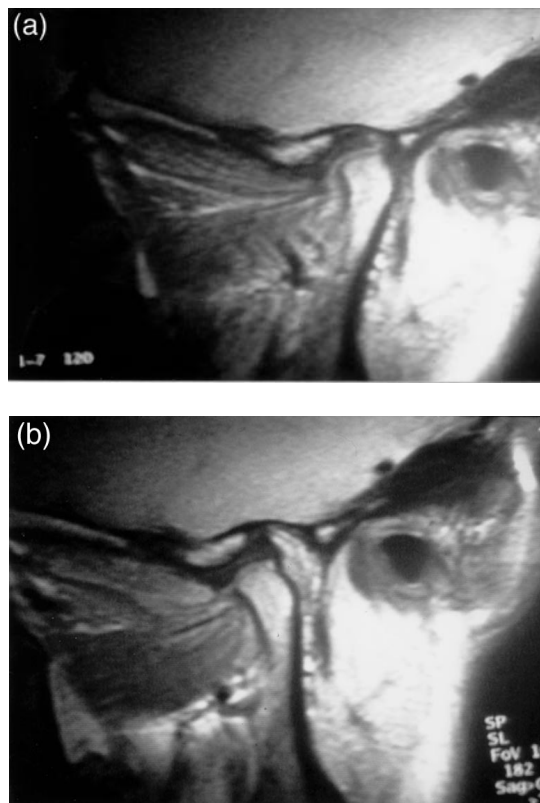


Figure 10 MRIs of the same patient after bite correction and insertion of a bite plane; physiological position of the condyles and disc-condyle relationship. (a) Closed mouth. (b) Open mouth.

of the ANB angle and harmonization of the profile and the MRIs a normal shape of the condyles and normal disc-condyle relationships with open and closed mouth (Figure 10a,b).

Celenza (1973) and Calagna *et al.* (1973) found that after muscle training or prolonged splint wear and, thus, after muscle deprogramming, patients could move the mandible further dorsally than before (centric). This observation is relevant to the findings in this investigation regarding the position of the condyle in relation to the mandibular fossa.

A posterior position (positive value) was found in 75 per cent of the joint deviations from the Y axis. These findings are inconsistent with results reporting an anterior position of the condyles after 'bite jumping' (Ruf and Pancherz, 1998). The posterior position of the joints found

in the present study is probably due to the bite plane being inserted for 2 weeks (Williamsone *et al.*, 1977, 1978). It served both for the disclusion and deprogramming of the muscles and may have caused a dorsal movement of the joints. In contrast, the images of the joints used in former studies were produced no later than 4 days after discontinuation of the treatment devices by which the mandible was kept in a permanent ventral position and, consequently, the muscles were adapted. This position of the mandible is maintained for some days without muscular deprogramming and disclusion, even if no bony adaptation and remodelling have occurred.

Conclusions

From the findings of this study, it may be concluded that mandibular growth and morphological translation occur upon insertion of functional orthopaedic appliances, particularly when the mandible is maintained in the therapeutic position by means of vertical elastics. This conclusion is in agreement with earlier findings of animal experiments and clinical trials regarding the effects of functional orthopaedic appliances (Eschler, 1952, 1954, 1963; Derichsweiler, 1958; Baume and Derichsweiler, 1961; Charlier *et al.*, 1969; Payne, 1971; Stöckli and Willert, 1971; Stöckli, 1972; McNamara *et al.*, 1975; Petrovic *et al.*, 1975, 1976; Stutzmann and Petrovic, 1975, 1986; Komposch, 1982; DeVincenzo *et al.*, 1987; Petrovic and Stutzmann, 1988).

Successful bite jumping, implying bone and muscle adaptation, results in a normal position of the mandibular fossa, the condyles, and the disc-condyle relationship, due to adaptation and remodelling of the joint structures following displacement.

Address for correspondence

Dr Nezar Watted
Poliklinik für Kieferorthopädie
Pleicherwall 2
D-97070 Würzburg
Germany

References

- Academy of Prosthodontics 1994 Glossary of prosthodontic terms. *Journal of Prosthetic Dentistry* 71: 41–112
- Armstrong N M 1971 Controlling the magnitude, duration and direction of extra oral force. *American Journal of Orthodontics* 59: 217–243
- Baume L J, Derichsweiler H 1961 Is the condylar growth center responsive to orthodontic therapy? An experimental study in *Macaca mulatta*. *Oral Surgery* 14: 347–362
- Bell W H, Yamaguchi Y 1991 Condyle position and mobility before and after intraoral vertical ramus osteotomies and neuromuscular rehabilitation. *International Journal of Adult Orthodontics and Orthognathic Surgery* 6: 97–104
- Boucher L J, Jacoby J 1968 Posterior border movements of the human mandible. *Journal of Prosthetic Dentistry* 20: 106–113
- Braun S 1996 Achieving improved visualization of the temporomandibular joint condyle and fossa in the sagittal cephalogram and a pilot study of their relationships in habitual occlusion. *American Journal of Orthodontics and Dentofacial Orthopedics* 109: 635–638
- Calagna L, Silverman S, Garfinkel L 1973 Influence of neuromuscular conditioning on centric relation registrations. *Journal of Prosthetic Dentistry* 30: 598–605
- Celenza F V 1973 The centric position: replacement and character. *Journal of Prosthetic Dentistry* 30: 591–598
- Charlier J P, Petrovic A, Hermenn-Stutzmann J 1969 Effects of mandibular hyperpropulsion on the prechondroblastic zone of young rat condyle. *American Journal of Orthodontics* 55: 71–74
- Coben S E 1971 The biology of Class II treatment. *American Journal of Orthodontics* 59: 470–487
- Dawson P E 1995 New definition for relating occlusion to varying conditions of the temporomandibular joint. *Journal of Prosthetic Dentistry* 74: 619–627
- Derichsweiler H 1958 Experimentelle Tieruntersuchungen über Veränderungen des Kiefergelenks bei Bißverschiebungen. *Fortschritte der Kieferorthopädie* 19: 30–44
- DeVincenzo J P, Huffer R A, Winn M W 1987 A study in human subjects using a new device designed to mimic the protrusive functional appliances used previously in monkeys. *American Journal of Orthodontics and Dentofacial Orthopedics* 91: 213–224
- Drace J E, Enzmann D R 1989 Defining the normal temporomandibular joint: closed-, partially open-, and open-mouth MR imaging of asymptomatic subjects. *Radiology* 177: 67–71
- Drace J E, Young S W, Enzmann D R 1990 Temporomandibular joint meniscus and bilaminar zone: MR imaging of the substructure-diagnostic landmarks and pitfalls of interpretation. *Radiology* 178: 73–81
- Eschler J 1952 Die muskuläre Wirkungsweise des Andresen-Häupl'schen Apparates. *Österreichische Zeitschrift für Stomatologie* 49: 79–88
- Eschler J 1954 Muskelfunktion und kieferorthopädische Therapie. In: Zahn-, Mund- und Kieferheilkunde,

- Handbuch für die zahnärztliche Praxis, Bd. V. Urban & Schwarzenberg. München, pp. 253–276
- Eschler J 1963 Form und Funktion im Kausystem. Fortschritte der Kieferorthopädie 24: 247–265
- Gerber A 1964 Logik und Mystik der Kiefergelenkbeschwerden. Schweizerische Monatsschrift für Zahnheilkunde 74: 687–697
- Gerber A 1970 Okklusionslehre, Okklusionsdiagnostik und Okklusionsbehandlung im Wandel unserer Aspekte. Schweizerische Monatsschrift für Zahnheilkunde 80: 447–470
- Gerber A 1971 Kiefergelenk und Zahnokklusion. Deutsche Zahnärztliche Zeitschrift 26: 119–141
- Gerber A 1978a Okklusionsdiagnostik bei defektem und prothetisch versorgtem Gebiß 1. Teil. Zahnärztliche Welt/Reform 87: 436–447
- Gerber A 1978b Okklusionsdiagnostik bei defektem und prothetisch versorgtem Gebiß 2. Teil. Zahnärztliche Welt/Reform 87: 488–496
- Gianelly A A 1998 A strategy for nonextraction Class II treatment. Perspectives on Class II treatment. Seminars in Orthodontics 4: 26–32
- Gianelly A A, Brosnan P, Martignoni M, Bernstein L 1983 Mandibular growth, condyle position, and Fränkel appliance therapy. Angle Orthodontist 53: 131–139
- Glatzl B 1993 Vergleichende Studie über die Anatomie des Kiefergelenks und seine Darstellung in der Magnetresonanztomographie. Wiener Klinische Wochenschrift 105: 560–563
- Häupl K, Psansky R 1939 Experimentelle Untersuchungen über Gelenktransformation bei Verwendung der Methoden der Funktionskieferorthopädie. Deutsche Zahn-, Mund- und Kieferheilkunde 6: 439–448
- Ismail Y H, Rokni A 1980 Radiographic study of condylar position in centric relation and centric occlusion. Journal of Prosthetic Dentistry 43: 327–330
- Kamelchuk L S, Grace M G A, Major P W 1996 Postimaging temporomandibular joint space analysis. Journal of Craniomandibular Practice 14: 23–29
- Katzberg R W, Keith D A, Ten Eick W R, Guralnick W C 1983 Internal derangements of the temporomandibular joint: an assessment of condylar position in centric occlusion. Journal of Prosthetic Dentistry 49: 250–254
- Katzberg R W *et al.* 1985a Magnetic resonance imaging of the temporomandibular joint meniscus. Oral Surgery, Oral Medicine, Oral Pathology 59: 332–335
- Katzberg R W, Miller T L, Hayakawa K, Manzione J V, Tallents R H 1985b Temporomandibular joint arthrography: comparison of morbidity with ionic and low osmolarity contrast media. Radiology 155: 245–246
- Komposch G 1982 Eine tierexperimentelle Studie zur Reaktionsfähigkeit der temporomandibulären Strukturen auf kieferorthopädische Maßnahmen. Fortschritte der Kieferorthopädie 43: 407–431
- Kubein D, Jähnig A 1983 Zur Biomechanik des menschlichen Kiefergelenkes. Deutsche Zahnärztliche Zeitschrift 38: 32–39
- McNamara J A, McDougall P D, Dierks J M 1966 Arch width development in Class II patients treated with extra-oral force and functional jaw orthodontics. American Journal of Orthodontics 52: 353–359
- McNamara J A, Conelly T G, McBridge M C 1975 Histological studies of temporomandibular joint adaptations. In: McNamara J A (ed.) Control mechanisms in craniofacial growth, Monograph No. 3, Craniofacial Growth Series. Center for Human Growth and Development, University of Michigan, Ann Arbor, pp. 209–227
- Owen A H III 1984a Orthodontic/orthopedic treatment of craniomandibular pain dysfunction. Part 1: diagnosis with transcranial radiographs. Journal of Craniomandibular Practice 2: 238–249
- Owen A H III 1984b Orthodontic/orthopedic treatment of craniomandibular pain dysfunction. Part 2: posterior condylar displacement. Journal of Craniomandibular Practice 2: 333–349
- Owen A H III 1984c Orthodontic/orthopedic treatment of craniomandibular pain dysfunction. Part 3: anterior condylar displacement. Journal of Craniomandibular Practice 3: 31–45
- Payne G S 1971 The effect of intermaxillary elastic force on the temporomandibular articulation in the growing macaque monkey. American Journal of Orthodontics 60: 491–504
- Petrovic A G, Stutzmann J 1988 Reaktionsfähigkeit des tierischen und menschlichen Kondylenknorpels auf Zell- und Molekularebene im Lichte einer kybernetischen Auffassung des fasziellen Wachstums. Fortschritte der Kieferorthopädie 49: 405–425
- Petrovic A G, Oudet C, Gasson N 1973 Effets des appareils de propulsion et de retropulsion mandibulaire sur le nombre des sacromeres en serie du muscle pterygoidien externe et sur la croissance du cartilage condylien du jeune rat. Orthodontie Française 44: 191–212
- Petrovic A G, Oudet C, Stutzmann J, Gasson N 1974 Kontrollfaktoren des Kondylenwachstums. Fortschritte der Kieferorthopädie 35: 347–364
- Petrovic A G, Gasson N, Oudet C 1975 Wirkung der übertriebenen posturalen Vorschubstellung des Unterkiefers auf das Kondylenwachstum der normalen und der mit Wachstumshormon behandelten Ratte. Fortschritte der Kieferorthopädie 36: 86–97
- Petrovic A G, Oudet C, Stutzmann J 1976 Behandlungsergebnisse hinsichtlich der Dauer übertriebenen posturalen Vorschubstellung des Unterkiefers. Tierexperimentelle Untersuchungen über den Mechanismus des Rückfalls. Fortschritte der Kieferorthopädie 37: 40–51
- Posselt U 1952 Range of movement of the mandible. Journal of the American Dental Association 56: 10–16
- Reuther J 1988 Kooperation zwischen Kieferorthopädie und Kieferchirurgie. Praktische Kieferorthopädie 2: 177–186
- Ricketts R M 1952 A study of changes in temporomandibular relation associated with the treatment of Class II malocclusion. American Journal of Orthodontics 38: 918–933

- Ruf S, Pancherz H 1998 Temporomandibular joint growth adaptation in Herbst treatment: a prospective magnetic resonance imaging and cephalometric roentgenographic study. *European Journal of Orthodontics* 20: 375–388
- Schellhas K P, Wilkes C H, Fritts H M, Omlie H M, Lagrotteria L B 1989 MR of osteochondritis dissecans and avascular necrosis of the mandibular condyle. *American Journal of Neuroradiology* 10: 3–12
- Stöckli P W 1972 Die Reaktionsfähigkeit des mandibulären Gelenkknorpels auf orthopädische Stimulation während der Wachstumsphase. *Schweizerische Monatsschrift für Zahnheilkunde* 82: 335–379
- Stöckli P W, Willert H G 1971 Tissue reactions in the temporomandibular joint resulting from anterior displacement of the mandible in the monkey. *American Journal of Orthodontics* 60: 142–155
- Stutzmann J, Petrovic A 1975 Tierexperimentelle Untersuchungen über Zusammenhänge zwischen Zunge, Musculus pterygoideus lateralis, mandibulärem Kondylenknorpel und Gaumennaht. *Fortschritte der Kieferorthopädie* 36: 354–373
- Stutzmann J, Petrovic A 1986 Ist der Bionator ein orthopädisches und/oder ein orthodontisches Gerät? *Fortschritte der Kieferorthopädie* 47: 254–280
- Stutzmann J, Petrovic A 1987 Durch Bionator verursachtes zusätzliches Längenwachstum des Unterkiefers beim Kind. Stellungnahme zur Wirkungsweise von funktionskieferorthopädischen Geräten. *Fortschritte der Kieferorthopädie* 48: 556–558
- Tasaki M M, Westesson P L 1993 Temporomandibular joint: diagnostic accuracy with sagittal and coronal MR imaging. *Radiology* 186: 723–729
- Teuscher U 1976 Prinzipien extra-oraler Kräfte. Informationen aus Orthodontie und Kieferorthopädie 7: 9–16
- Teuscher U 1978 A growth-related concept for skeletal Class II treatment. *American Journal of Orthodontics* 74: 258–275
- Teuscher U 1979 Ein Konzept zur Behandlung der skelettalen Klasse II unter Berücksichtigung des Wachstums. Information aus Orthodontie und Kieferorthopädie 11: 41–61
- Vardimon A D, Stutzmann J, Graber T M, Petrovic A M 1989 Functional orthopedic magnetic appliance (FOMA II)—modus operandi. *American Journal of Orthodontics and Dentofacial Orthopedics* 95: 371–387
- Vardimon A D, Graber T M, Voss L R, Muller T P 1990 Functional orthopedic magnetic appliance (FOMA III)—modus operandi. *American Journal of Orthodontics and Dentofacial Orthopedics* 97: 135–148
- Vogl T J, Kellertmann O, Randzio J 1988 Ergebnisse der Kernspintomographie mittels optimierter Oberflächenspule. *Fortschritte der Röntgenstrahlen* 149: 502–511
- Weinberg L A 1972 Technique for temporomandibular joint radiographs. *Journal of Prosthetic Dentistry* 28: 284–308
- Wilk R M, Wolford L M 1989 Magnetic resonance imaging of the temporomandibular joint with surface coil. *Oral and Maxillofacial Surgery* 44: 135–142
- Williamsone E H, Evans D L, Barton W A, Williams B H 1977 The effect of bite plane use on terminal hinge axis location. *Angle Orthodontist* 47: 25–30
- Williamsone E H, Caves S A, Edenfield R J, Morse P K 1978 Cephalometric analysis: comparisons between maximum intercuspation and centric relation. *American Journal of Orthodontics* 74: 672–681
- Witt E 1973 Muscular physiological investigations into the effect of bimaxillary appliance. *Transactions of the European Orthodontic Society*, pp. 448–450
- Witt E 1988 Extraktion im Rahmen der Kieferorthopädie. In: Schmuth, G. *Kieferorthopädie II, Praxis der Zahnheilkunde*. Urban & Schwarzenberg. München, pp. 107–149
- Witt E 1996 Behandlungskonzepte. In: Miethke R R, Drescher D (eds) *Kleines Lehrbuch der Angle-Klasse II, I unter besonderer Berücksichtigung der Behandlung*. Quintessenz, Berlin, pp. 93–106
- Witt E, Watted N 1999 Effectiveness of intra- and extra-oral aids to the bionator. A controlled study within the scope of the 'Würzburg concept'. *Journal of Orofacial Orthopedics* 60: 269–278
- Witt E, Sahn G, Hevia R 1990 Der Bionator mit anteriorem Hochzug—Das Würzburger Konzept. Teil I. *Praktische Kieferorthopädie* 4: 285–292

Copyright of European Journal of Orthodontics is the property of Oxford University Press / UK and its content may not be copied or emailed to multiple sites or posted to a listserv without the copyright holder's express written permission. However, users may print, download, or email articles for individual use.